

# CASE STUDY

## Resolution of Nocturnal Enuresis, Constipation, Headaches, Allergies & Cold Hands in a 6-Year-Old Male Following Chiropractic for Vertebral Subluxation: Case Study & Review of the Literature

Russell Herring, DC<sup>1</sup> & Danielle Wright, DC<sup>2</sup>

### Abstract

**Objective:** To report on the positive health outcomes of a child with multiple co-morbidities undergoing chiropractic care.

**Clinical Features:** Parents presented a 6-year-old male with a history of nocturnal enuresis, headaches, ADHD, asthma, allergies, constipation, earaches, and cold hands. The patient had been prescribed and taking several different medications including over the counter pain relievers, laxatives, Qvar (beclomethasone dipropionate) inhaler, Nasonex, Albuterol, Benadryl, and Claritin. Clinical examinations performed by the chiropractor revealed signs of vertebral subluxation.

**Intervention and Outcomes:** A diversified chiropractic technique was applied combining motion and static palpation, pelvic protocols from Thompson Terminal Point Technique and implementation of the Activator and Integrator adjusting instruments. After twenty adjustments complete resolution of enuresis was reported. On the twenty-fifth visit, the patient's parents reported complete resolution of cold hands and constipation, as well as 80% relief of all remaining symptoms.

**Conclusion:** This study presents relief of nocturnal enuresis, headaches, ADHD, asthma, allergies constipation, earaches, and cold hands in a 6-year-old male following chiropractic adjustments. Further research is suggested to explore the value of chiropractic management of patients with nocturnal enuresis.

**Key Words:** *chiropractic, subluxation, nocturnal enuresis, adjustment, headaches, pediatric, constipation, ADHD, asthma, allergies*

### Introduction

Nocturnal enuresis (NE) is a common condition occurring in up to 15% of seven year olds who show no symptoms during the day, but still void at night.<sup>1</sup> Research shows that NE is more common in boys than girls, and can commonly be associated with encopresis and behavioral disorders such as ADHD.<sup>2</sup> Even though chances of self-correction diminishes as the patient grows older, this condition has been previously

said to be self-limiting. New research shows that NE can be malignant. It can remain through childhood, and when not properly addressed and treated, is diagnosed in up to 1% of adults.<sup>1,3</sup> There is continuing debate on whether this condition is physiologically or anatomically based which is still being deliberated, but recent studies support research that shows NE as multifaceted disorder consisting of multiple pathological factors including genetics, in addition to psychological and anatomical issues.<sup>3</sup>

- 
1. Private Practice of Chiropractic, Auburn, AL
  2. Private Practice of Chiropractic, Hoschton, GA

Because the pathophysiology is so complex, and due to the fact that most medical training programs do not assess NE as a priority, conventional management of this condition is often vague and futile.<sup>4</sup> In addition, the information most readily available to families is mostly inaccurate, making the management of this condition even more difficult.<sup>4</sup> Nonetheless, medical treatments typically include nighttime bells or alarms, medications such as tricyclic antidepressants, behavioral rewards and punishments, requirement of voiding before sleep, and limitation of nighttime fluids.<sup>1,3-4</sup> This specific case study addresses chiropractic management of nocturnal enuresis, which ultimately focuses on analysis of the nervous system and detection of vertebral subluxation causing dysfunction in the body.

## Case Report

### *History*

A six-year-old boy suffering from a multitude of complaints, including nocturnal enuresis, was brought to a chiropractor's office seeking relief of his everyday symptoms. His parents described additional complaints associated with headaches, constipation, earaches, allergies, asthma, cold hands, and ADHD. The child's enuresis, ADHD, and headaches had been persistent since birth. Bedwetting occurrences were described as happening every night, with multiple occasions each night. According to a detailed family history, both the child's mother and father had previously experienced similar symptoms associated with asthma and allergies. Additionally, the patient's father suffered from ADHD, bed-wetting, digestive problems, fibromyalgia, and headaches.

At birth, the patient weighed five pounds, ten ounces and measured nineteen and one half inches. He was breastfed for six months and received Similac formula the following twelve. According to his mother, other than the aforementioned symptomatology, the patient led a life involved heavily in exercise and activities including soccer, running, biking, swimming, and wrestling.

Upon initial presentation, the patient was being treated with multiple medications for asthma, allergies, constipation, and headaches. Some of these medications include: Qvar (beclomethasone dipropionate) inhaler, Nasonex, Albuterol, Advil, Tylenol, Benadryl, Claratin, cough syrups, and laxatives, all prescribed by his pediatrician.

### *Examination*

The preliminary visit consisted of a consultation including a detailed history and explanation of symptomatology, surface electromyography to evaluate neurological and muscle function, and postural x-rays (figures 1-3) to assess for subluxation, pathology, and abnormal curvature. The x-rays revealed the bone density adequate with no evidence of fractures, dislocations, or osseous pathologies. No adjustments were performed at the first visit. A care plan was established consisting of a projected forty-two visits over a one-year period, including three progressive reevaluations at months three, six, and twelve. At the time of this study, the patient had received twenty-four weeks of care.

A surface electromyography (SEMG) scan was performed to analyze paraspinal muscle tone. The muscles that are analyzed support the spinal bones and receive direct innervation from nerves branching off the spinal cord. The SEMG measures action potentials, or electrical potentials, to determine the amplitude of muscle tension.<sup>5</sup> The muscle measurements are represented with four possibilities: mild elevation of tone, moderate elevation, high elevation, and/or tones that are lower than normal amplitude.

According to Kent, dysfunction of the paraspinal musculature is generally accepted as a clinical manifestation of vertebral subluxation.<sup>5</sup> The SEMG scan provides objective data regarding the changes in paraspinal muscle function that accompany subluxation.<sup>5</sup> This patient's SEMG scan demonstrated severe increases in tension throughout the spine, including the cervical, thoracic, and sacral regions, as noted in Figure 4.

Upon the second visit in the office, both motion and static palpation were utilized to assess for areas of subluxation in the spine. The patient was lying prone while the doctor palpated the cervical, thoracic, lumbar, pelvic and sacral areas. A leg length analysis using Thompson Terminal Point Technique was also employed.

During static palpation, the doctor evaluated the spine and surrounding musculature for changes in symmetry and spasms, as well as edematous changes, inflammation, and areas of tenderness. When motioning the spine, the doctor used a posterior to anterior directional force to measure degrees of movement between vertebral segments. According to the leg length analysis, the patient presented with balanced leg length, however the doctor noted presentation of internal rotation of the right leg, and decreased range of motion at the right SI joint. Decreased ranges of motion were also found at T2 and L3. Left laterality of the L3 vertebrae and occipital bones were also present. Based on palpatory and analytical findings, the right SI joint, L3, T2, and the left occiput were adjusted in their respective proper lines of correction using the Activator Adjusting Instrument.

### *Intervention*

Chiropractic care was provided for thirty-two visits over a period of twenty-four weeks at the time this study was conducted. During each office visit, subluxations were detected based on a Thompson leg check, static palpation, and motion palpation. Each subluxation was adjusted using a diversified chiropractic technique with the assistance of either the Activator or Integrator adjusting instruments.

In those thirty-two visits, the most common subluxations were identified in the cervical, lumbar, and pelvic areas. Twenty-six adjustments were delivered to the right pelvis and twenty-four to the left occiput. In addition to these two segments, C1 (atlas), C2 (axis), T1, T2, L1, L2, and L3 were often adjusted.

Table 1 details each specific vertebral segment that received adjustments during care. Every adjustment was performed with the patient in the prone position with either the Activator or the Integrator adjusting instruments.

### *Thompson Terminal Point*

Created by J. Clay Thompson, Thompson Terminal Point is a technique that requires specific investigation of both the spine and pelvis. The pelvic analysis is based on two positions. First, length of the legs is evaluated while in extension and the patient is lying prone.<sup>6</sup> This is termed position one. Secondly, still in a prone position, the knees are flexed to 90 degrees and leg length is again analyzed.<sup>6</sup> This is known as position two.

There are two Derifield categories including the possibility of a short leg in position one lengthening in position two, known as a positive Derifield (+D) listing. A second presentation, a short leg in position one that either balances or remains short in position two is known as a negative Derifield (-D) listing. With the presentation of a +D the patient has a posterior inferior ilium on the side of the short leg.<sup>6</sup> A -D presentation indicates an anterior and inferior sacrum opposite the side of short leg.<sup>6</sup> When following the full Thompson Terminal Point Technique, the doctor would use a specifically designed drop table, to deliver a high velocity, low force thrust at the appropriate segment in the correct line of drive to correct the restriction.

### *Activator II Adjusting Instrument*

When this doctor deemed necessary, the patient's vertebrae and pelvis were adjusted using the Activator II Adjusting Instrument (AAI) while the patient was lying prone. In 1997, the AAI received a 510K Class II designation from the FDA.<sup>7</sup> The AAI, when used appropriately, can adjust vertebral subluxations in a linear correction with a high velocity, low amplitude force, producing advanced specificity during a chiropractic adjustment. Results from consistent studies conducted specifically on the AAI show that an adjustment produced enough energy to relatively move the vertebrae, but energy levels so low that risk of injury is miniscule.<sup>8</sup>

### *Integrator Adjusting Instrument*

This doctor also used the Integrator Adjusting Instrument while the patient was prone. In 1995, the Integrator received a 510K Class II designation from the FDA.<sup>9</sup> It has been tested and is capable of delivering a three-dimensional adjustment including the typical linear line of drive, but can also include a right and left torque component if necessary.<sup>9</sup> The Integrator has a pressure sensitive tip in order to deliver a reproducible toggle recoil that is activated with the same amount of pressure each time the instrument is fired.<sup>9</sup> The thrust is delivered at 1/10,000 of a second, allowing for a considerable reduction in amplitude delivered to the patient's spine.<sup>9</sup> High velocity, low amplitude adjusting instruments were utilized in this case because of their low risk and high specificity.

### *Outcomes*

After every adjustment, the doctor reassessed motion in the spine and reported that the patient had tolerated all adjustments well. As treatments progressed, the parents noticed a decrease in the number of times the child would have a wet night, and at the twenty-first visit in the office, the parents reported that the child had not had a wet night in over a week.

At sixteen weeks of care, the 25<sup>th</sup> chiropractic adjustment was delivered, and the first reevaluation was conducted. According to the patient's parents, symptoms from enuresis, cold hands, and constipation completely resolved. His parents also reported an overall improvement of 80% in regard to the remaining conditions including ear infections, allergies, asthma, ADHD, and headaches. Recounted by the parents, it was noted that the child no longer takes over the counter pain relievers but is still on medication for his allergies and asthma.

## **Discussion**

### *Etiology*

The cause of nocturnal enuresis has been extensively contested. The argument continues as recent studies support research that shows NE as intricate disorder consisting of pathological factors including neurology, anatomy, sleeping conditions, psychological and behavioral roles, and genetics.

Children with NE have long been thought to have delays in the development or abnormalities of the central nervous system. Multiple studies have shown conflicting views of the idiosyncrasies present; whether the child has an overactive sympathetic or parasympathetic nervous system, has yet to be confirmed.<sup>10</sup> The most obvious potential problem that may be present in a patient with NE, although it has not been established true in all patients, is a discrepancy between the child's bladder capacity and an increased diuresis rate at night.<sup>3,10</sup>

In a large portion of cases, parents claim that their child suffering with NE are just "deep sleepers" and don't wake up in time; while other parents have also dealt with NE and are now learning that genetics can take an impact.<sup>10</sup> Some literature, including the DSM-5, even focuses on the role of psychological factors in the pathogenesis of this condition, stating that bed-wetting is commonly link with ADHD in children.<sup>2,10-11</sup>

### *Medical Intervention*

Because the pathophysiology is so complicated, conventional treatment of this condition is often too broad, and can be erratic.<sup>4</sup> Nonetheless, medical treatments can include any of the following:

1. Medications
2. Nighttime alarms
3. Reinforced behavioral habits

The most common medication used to treat a child with nocturnal enuresis is tricyclic antidepressants. According to Caldwell's research based on these medications, the initial outcome proved that the medication worked.<sup>12</sup> However, during the ingestion of the antidepressants, there were common adverse effects in the patients including: dizziness, headaches, mood changes, gastrointestinal discomfort, and neutropenia.<sup>12</sup> Another disadvantage noted is that most of the children relapsed and started experiencing wet nights again once the medication was stopped.<sup>10,12</sup>

Nighttime bells and alarms have been proven to be more

effective than tricyclic antidepressants.<sup>13</sup> Studies support that most children treated with alarms maintain dry nights after the treatment has stopped, and that purposefully increasing the amount of fluid before bedtime, toward the end of the treatment, has decreased the number of relapses in NE patients treated with alarms.<sup>13,14</sup>

The application of specific behavioral habits, including decreased fluid intake and voiding before bed, as well as a mid-night wake up schedules may seem intuitive for parents of NE children. All of these interventions show a decreased incidence in wet nights. Typically, specific routines can be used along with nighttime alarms to develop a dependable treatment in order to obtain the best results without any dire side effects from taking medication.

Although the patient will see great results using these methods, families still should take into consideration the difficulty of developing these strict schedules and habits. Not only that, but the child lacks confidence and is typically unwilling to partake in any sleepovers at a friend's house. Until the confidence is built, the child is subject to anxiety or potential depression dealing with the symptomatology of enuresis that will affect his or her life.

#### *Integrated Intervention*

Because nocturnal enuresis can be a major burden on the patient, physically and emotionally, and the family members in the household, multiple alternative options have been presented to patients in order to experience some relief. Assorted studies have shown that hypnosis has resulted in the relief of symptoms related to enuresis with minimal relapses because children make great hypnotic candidates.<sup>10</sup>

Another option is acupuncture, which focuses on the removal of energy imbalances that may affect certain organs, like the kidneys and bladder. Nonetheless, results are often sporadic in treating NE with acupuncture, just like other treatment methods.<sup>10</sup> According to a study conducted by Zheng-tao, most participants benefited from acupuncture therapy no more than those who use typical medication; however, Culbert reports a few studies on acupuncture and relief of nocturnal enuresis.<sup>10,15</sup>

Besides hypnosis and acupuncture, other changes can be made to the child's lifestyle that can help, including a specific diet and herbal supplements, as also noted by Culbert.<sup>10</sup>

#### *Chiropractic Mechanism, Intervention, and Literature Review*

The World Health Organization defines subluxation as: "A lesion or dysfunction in a joint or motion segment in which alignment, movement integrity and/or physiological function are altered, although contact between joint surfaces remains intact. It is essentially a functional entity, which may influence biomechanical and neural integrity."<sup>16</sup> Aforementioned, neurological deficits are a proposed mechanism of NE in children. This directly suggests potential benefits in enuresis with the implementation of chiropractic care, which focuses on removal of nerve compression creating deficits.

When a spinal bone shifts out of proper alignment, the

intervertebral foramen, where nerve roots extend from the spinal cord, is obstructed.<sup>17</sup> Kent notes that DD and BJ Palmer state that subluxation occurs when there is pressure on a nerve, and that both kinesiological and neurological dysfunction occur during subluxation.<sup>18</sup>

Kent also discusses studies performed on animals that represent nerve damage when compression was applied, and thoroughly explains that nerve roots coming off the spinal cord are especially susceptible due to their lack perineurium and epineurium.<sup>18</sup> This suggests that biomechanical dysfunction leads to neural compromise. This compromise provides an inhibited environment for nerve function, creating abnormal central nervous system processing.<sup>18</sup>

Subluxation based chiropractic treatment aims to relieve nerve compression by reinstating proper alignment of the vertebra. Treatment of subluxations causing neuronal dysfunction intends to remove nerve compression and therefore aid the body in maintaining peak function overall. One study describes a proposed subluxation at the sacral or pelvic area influencing the neural integrity of the pelvic splanchnic nerves, which directly innervate the bladder and its associated musculature.<sup>19</sup> As noted by Hafer and Alcantara, subluxation here can potentially activate these nerves at unsuitable times, causing nocturnal enuresis. They reported improvements of enuresis in a ten-year-old girl who was experiencing frequent wet nights after using antibiotics for multiple urinary tract infections.<sup>19</sup>

Many other studies have reported improvements of nocturnal enuresis even though chiropractic literature as a whole has not determined a consistent level of effectiveness. One article describes a child who had been a "bed-wetter all of his childhood" developing nocturnal bladder control with the implementation of chiropractic care when medical intervention could provide no relief.<sup>20</sup>

In a rather large clinical study, 171 NE patients received adjustments from chiropractic students in Australia. The study noted that at least 70% of these children had parents who also had nocturnal enuresis.<sup>21</sup> The results concluded that twenty-five percent of the original cases were considered "successes", meaning that the patients experienced a reduction in wet nights of at least 50% after receiving chiropractic care.<sup>19</sup> Although this study shows less than unyielding results, there is representation of a single chiropractic adjustment relieving NE symptoms for at least a month's time.<sup>22</sup> There is also clinical significance in a study conducted by Reed et al. in which different chiropractic students delivered adjustments to NE patients who averaged 9.1 wet nights every two weeks pre-treatment.<sup>23</sup> The results from this study represent a mean wet night frequency of 7.6 nights per every two weeks after receiving care.<sup>23</sup>

In a case study of 33 patients ranging from three to eighteen years old conducted by van Poek and Cunliffe represents an overall resolution of 66.6%.<sup>24</sup> These results signify a favorable outcome of chiropractic intervention when compared to conventional medicine, as well as alternative treatments such as hypnotherapy, acupuncture, and biofeedback therapy.<sup>24</sup>

Neally and Alcantara report positive results in a case study

including a 10-year-old male who was brought to a chiropractor clinic to treat neck pain after falling off a trampoline.<sup>25</sup> The patient in the study was diagnosed with Asperger's syndrome and enuresis at an early age. The authors noted that the intern treating the patient was initially used a diversified technique and no substantial results were ensuing.<sup>25</sup> After the tenth adjustment the intern providing care switched to Logan Basic Technique to focus on the parasympathetic nervous system because the child seemed hyperactive.<sup>25</sup> Following the first Logan adjustment, the patient was calm relaxed, and bedwetting terminated. The patient continued receiving Logan Basic adjustments for 22 subsequent visits.<sup>25</sup>

Overall, the success of any of the many mentioned treatments depends mostly on the etiology of NE in each specific child. Krietz explains that behavioral therapy with alarms, as well as chiropractic care, has shown great effectiveness in NE treatment.<sup>26</sup>

### Limitations

The foremost limitation of this research is that it is a case study. Specifically, there is no control group to compare this specific patient's case to in order to wholly sequester the efficacy of chiropractic care with enuresis. An additional limitation is the probable misreading of the SEMG scan. This error could have been due to machine malfunction or human conduction error.

### Conclusion

This case report outlines the integration of multiple chiropractic techniques and instruments in the care of a six-year-old male presenting with symptoms of nocturnal enuresis, headaches, ADHD, asthma, allergies constipation, earaches, and cold hands. The Activator II and Integrator instruments were used, in accordance with Thompson Terminal Point protocols and palpation, to adjust spinal subluxations.

After twenty-one adjustments the patient's parents reported that symptoms of enuresis and other co-morbidities had resolved. This case demonstrates the value of an integrated technique application in adjusting subluxations in order to allow proper nervous system function in the human body. The patient is continuing to be seen for regular chiropractic adjustments and remains free of symptoms from enuresis. With the lacking conventional treatment and information of nocturnal enuresis, this study serves as a source for continued research on the application of conservative intervention.

### References

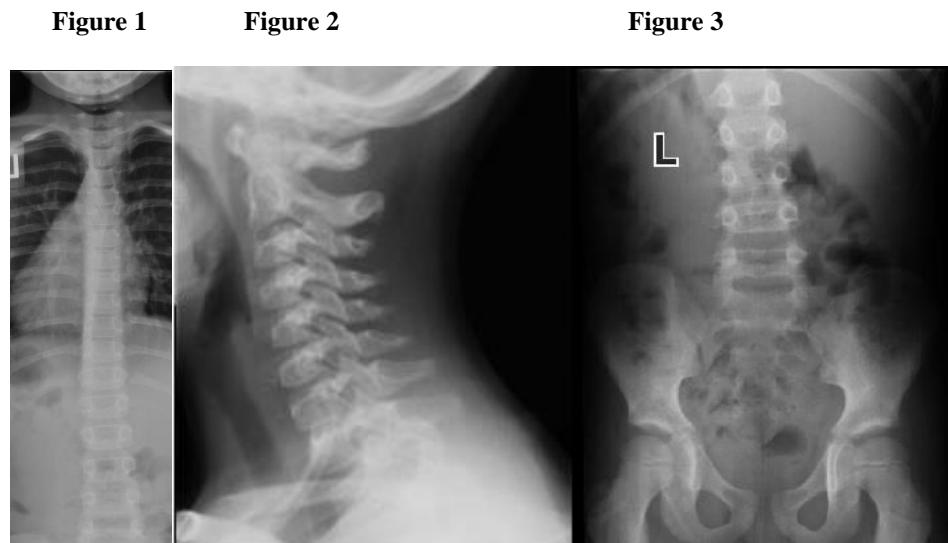
1. Hagstroem S, Kamperis K, Rittig S, Rijkhoff N, Djurhuus J. Monosymptomatic nocturnal enuresis is associated with abnormal nocturnal bladder emptying. *J Urol.* 2004 Jun;171(6):2562-6.
2. Mellon M, Natchev B, Katusic S, Colligan R, Weaver A, Voigt R et al. Incidence of enuresis and encopresis among children with attention-deficit/hyperactivity disorder in a population-based birth cohort. *Academic Pediatrics.* 2013;13(4):322-327.

3. Herzeele CV, Walle JV. Incontinence and psychological problems in children: a common central nervous pathway? *Pediatr Nephrol.* 2016Feb12.
4. Vande Walle J, Rittig S, Bauer S, Eggert P, Marschall-Kehrel D, Tekgul S. Practical consensus guidelines for the management of enuresis. *Eur J Pediatr.* 2012;171(6): 971-83.
5. Kent C. Surface electromyography in the assessment of changes in paraspinal muscle activity associated with vertebral subluxation: a review. *J Vert Sublux Res* 1997;1(3):15-22.
6. Cooperstein R. The derefield pelvic leg check: a kinesiological interpretation. *Chiropr Tech.* 1991;3(2):60-5.
7. Device Classification. *Accessdata.fda.gov.* 2016 [cited 27 February 2016]. Available from: [http://www.accessdata.fda.gov/scripts/cdrh/cfdocs/cfpmn/pmn\\_template.cfm?id=k973506](http://www.accessdata.fda.gov/scripts/cdrh/cfdocs/cfpmn/pmn_template.cfm?id=k973506)
8. Fuhr AW, Menke JM. Status of activator methods chiropractic technique, theory, and practice. *J Manipulative Physiol Ther.* 2005; 28(2): e1-e20
9. Holder JM. Chiropractic research earns international prestige: chiropractic care and state of well-being. *Can Chiropr.* 2001;6:22-23
10. Culbert TP, Banez GA. Wetting the bed: integrative approaches to nocturnal enuresis. *Explore (NY).* 2008;4(3):215-220.
11. Van Herzeele C, De Bruyne P, De Bruyne E, Walle JV. Challenging factors for enuresis treatment: psychological problems and non-adherence. *J Pediatr Urol.* 2015 Dec;11(6):308-13.
12. Caldwell PH, Sureshkumar P, Wong WC. Tricyclic and related drugs for nocturnal enuresis in children (review). (Cochrane Rev). *Cochrane Database Syst Rev.* 2016 Jan 20;1:CD002117.
13. Glazener C, Evans J, Peto R. Alarm interventions for nocturnal enuresis in children. (Cochrane Rev). *Cochrane Database Syst Rev.* 2005;18:CD002911.
14. Forsythe WI, Redmond A. Enuresis and the electric alarm: study of 200 cases. *Br Med J.* 1970 Jan 24;1(5690):211-3.
15. Lv ZT, Song W, Wu J, Yang J, Wang T, Wu CH, Gao F, Yuan XC, Liu JH, Li M. Efficacy of acupuncture in children with nocturnal enuresis: a systematic review and meta-analysis of randomized controlled trials. *Evid Based Complement Alternat Med.* 2015;2015:320701.
16. WHO Guidelines on Basic Training and Safety in Chiropractic. *Apps.who.int.* 2016 [cited 27 February 2016]. Available from: <http://apps.who.int/medicinedocs/en/d/Js14076e/>
17. RR. Palmer B, Kale M. The subluxation specific, the adjustment specific. [Spartanburg, S.C.]: [Kale Foundation]; 1986.
18. Kent C. Models of vertebral subluxation: a review. *J Vert Sublux Res.* 1996;1(1):1-7.
19. Hafer C, Alcantara J. Resolution of nocturnal enuresis following adjustment of vertebral subluxations: a case report. *J Pediatr Matern & Fam Health - Chiropr.* 2015 Win;2015(1):5-8.

20. Alcantara J, Weisberg, J. Resolution of nocturnal enuresis and vertebral subluxation in a pediatric patient undergoing chiropractic care: a case report & review of the literature. *J Pediatr Matern & Fam Health – Chiropr.* 2010; 4(3):143-149.
21. Leboeuf C, Brown P, Herman A, Leembruggen K, Walton D, Crisp TC. Chiropractic care of children with nocturnal enuresis: a prospective outcome study. *J Manipulative Physiol Ther* 1999;14(2):110-15.
22. Blomert PR. Functional nocturnal enuresis. *J Manipulative Physiol Ther*, 1994;17(5):335-8.
23. Reed WR, Beavers S, Reddy SK, Kern G. Chiropractic management of primary nocturnal enuresis. *J Manipulative Physiol Ther.* 1994;17(9):596-600.
24. van Poecke AJ, Cunliffe C. Chiropractic treatment for primary nocturnal enuresis: a case series of 33 consecutive patients. *J Manipulative Physiol Ther* 2009;32(8):675-81.
25. Neally R, Alcantara J. Resolution of chronic nocturnal enuresis in children with Asperger's syndrome following subluxation based chiropractic care: a case series. *J Pediatr Matern & Fam Health- Chiropr.* 2015;4(3):131-139.
26. Kreitz BG, Aker PD. Nocturnal enuresis: treatment implications for the chiropractor. *J Manipulative Physiol Ther.* 1994;17(7):465-73.

## Appendix

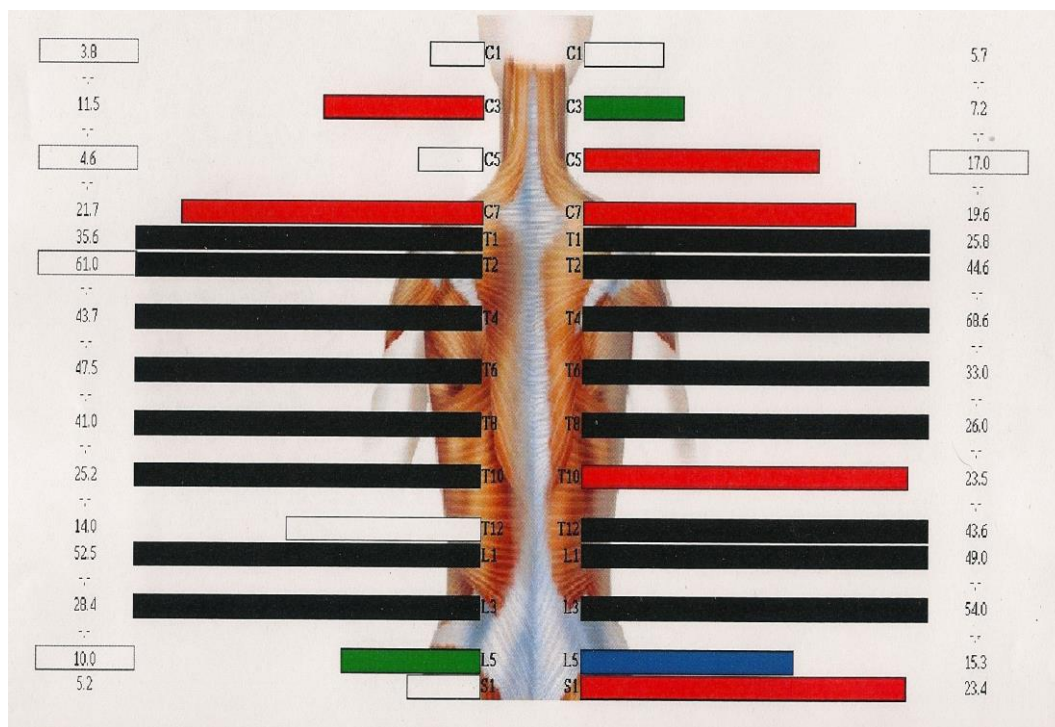
### Figures and Tables



**Figure 1.** Depiction of an anterior to posterior x-ray of the child's cervical, thoracic, and lumbar spine.

**Figure 2.** Depiction of a laterally projected x-ray of the child's cervical spine.

**Figure 3.** Depiction of an anterior to posterior x-ray of the child's lumbar spine and pelvis.



**Figure 4.** The paraspinal SEMG depicts abnormally high muscle tones at C3, C5, C7, T10, and S1, moderate readings at L5, and mild readings at C3 and L5.

<b>Region/Segment</b>	<b>Total</b>
<b>Cervical</b>	<b>27</b>
C0 (Occiput)	24
C1 (Atlas)	2
C2 (Axis)	1
<b>Thoracic</b>	<b>21</b>
T1	7
T2	14
<b>Lumbar</b>	<b>26</b>
L1	9
L2	13
L3	4
<b>Pelvis</b>	<b>26</b>
<b>Sacrum</b>	<b>7</b>

**Table 1.** A representation of every spinal adjustment that was delivered in the 24 weeks of care.